

The Neuroanatomical Basis of Understanding Sarcasm and Its Relationship to Social Cognition

S. G. Shamay-Tsoory and R. Tomer
Rambam Medical Center and University of Haifa

J. Aharon-Peretz
Rambam Medical Center

The authors explored the neurobiology of sarcasm and the cognitive processes underlying it by examining the performance of participants with focal lesions on tasks that required understanding of sarcasm and social cognition. Participants with prefrontal damage ($n = 25$) showed impaired performance on the sarcasm task, whereas participants with posterior damage ($n = 16$) and healthy controls ($n = 17$) performed the same task without difficulty. Within the prefrontal group, right ventromedial lesions were associated with the most profound deficit in comprehending sarcasm. In addition, although the prefrontal damage was associated with deficits in theory of mind and right hemisphere damage was associated with deficits in identifying emotions, these 2 abilities were related to the ability to understand sarcasm. This suggests that the right frontal lobe mediates understanding of sarcasm by integrating affective processing with perspective taking.

Irony is an indirect form of speech used to convey feelings in an indirect way. Ironic utterances are characterized by opposition between the literal meaning of the sentence and the speaker's meaning (Winner, 1988). One form of irony is *sarcasm*. Sarcasm is usually used to communicate implicit criticism about the listener or the situation. It is usually used in situations provoking negative affect and is accompanied by disapproval, contempt, and scorn (Sperber & Wilson, 1986). For example, a boss catching his employee taking a nap may remark "Joe, don't work too hard!" to express his disapproval. The listener must identify the opposition between the literal meaning of this sentence (Joe is working too hard) and the boss's intention to criticize Joe (Joe is a lazy worker). The ironic speaker intends that the listener detect the deliberate falseness; he makes a statement that violates the context and intends the listener to recognize this statement (Dennis, Purvis, Barnes, Wilkinson, & Winner, 2001). The interpretation of sarcasm thus involves understanding of the intentions expressed in the situation and may include processes of social cognition and theory of mind.

SARCASM AND SOCIAL COGNITION

It has been demonstrated that the use of sarcasm has several social communicative functions, such as increasing the perceived politeness of the criticism (Brown & Levinson, 1978), decreasing the perceived threat and aggressiveness of the criticism (Dews & Winner, 1995), and creating a humorous atmosphere (Dews &

Winner, 1995). It appears that a deficit in understanding sarcastic utterances may reflect an impaired ability to understand social cues such as intentions, beliefs, and emotions. In concordance, recent theories explaining irony have argued that sarcastic comments are interpreted in the light of their relevance to the situation. Sperber and Wilson's (1981) relevance theory advocates that the interpretation of ironic utterances may require recognition of the speaker's attitude and thus requires shared knowledge between the speaker and the listener.

A key aspect of social cognition is the ability to infer other people's mental state, thoughts, and feelings, commonly referred to as the *theory of mind* (ToM). Although irony has been investigated from a psycholinguistic perspective (e.g., Grice, 1978; Sperber & Wilson, 1981), recent findings in developmental and neuropsychological research suggest that understanding irony involves the understanding of social cues and requires ToM. Irony is only gradually mastered by young children. Developmental research studies have suggested that the difficulty that small children may have in understanding irony is related to their difficulties inferring the speaker's belief and intentions (Sullivan, Winner, & Hopfield, 1995; Winner & Leekam, 1991). Understanding irony requires first-order intentionality about the speaker's belief (to avoid interpreting irony as a mistake), as well as second-order intentionality about the speaker's beliefs about the listener's beliefs, to avoid interpreting irony as a lie (Dews & Winner, 1997). Happe (1993) has reported that among autistic children, impaired ability to attribute mental states relates to impaired ability to interpret irony. The same pattern of impairment has been reported in clinical populations of individuals with brain injury (Dennis et al., 2001). Winner, Brownell, Happe, Blum, and Pincus (1998) have suggested that individuals with right hemisphere brain damage are unable to distinguish lies from jokes and that this inability is related to a difficulty in attributing second-order mental states (Winner et al., 1998). Shamay, Tomer, and Aharon-Peretz (2002) have reported that prefrontal brain damage was associated with both impaired empathic ability and impaired ability to interpret ironic utterances, and these abilities were highly correlated in a group of frontal lobe-lesioned patients (Shamay et al., 2002).

S. G. Shamay-Tsoory and R. Tomer, Cognitive Neurology Unit, Rambam Medical Center, Haifa, Israel, and Department of Psychology and Brain and Behavior Center, University of Haifa, Haifa; J. Aharon-Peretz, Cognitive Neurology Unit, Rambam Medical Center.

S. G. Shamay-Tsoory was supported by a doctoral research grant from the Israel Foundation Trustees. We are grateful to Margo Lapidot for the Hebrew version of the Irony test.

Correspondence concerning this article should be addressed to S. G. Shamay-Tsoory, Department of Psychology and Brain and Behavior Center, University of Haifa, Haifa 31905, Israel. E-mail: sshamay@psy.haifa.ac.il

THE ANATOMICAL BASIS OF SARCASM

Previous research investigating the effects of brain damage on sarcasm has pointed to the role of the right hemisphere in pragmatic understanding (McDonald, 1999). Considerable research on adult participants has shown that the right hemisphere predominates in influencing the interpretation of conversation (Caplan & Dapretto, 2001; Rehak, Kaplan, & Gardner, 1992) and in understanding irony in particular (Brownell, Simpson, Bihle, Potter, & Gardner, 1990). Winner et al. (1998) have found that right hemisphere patients have difficulty interpreting inferential questions regarding counterfactual end comments of stories. With qualitative observations, researchers have also suggested that right hemisphere patients attribute the listener with perceiving the literal meaning of the utterance (Kaplan, Brownell, Jacobs, & Gardner, 1990). It has been suggested that the right hemisphere is involved in several paralinguistic domains, such as the prosodic elements of language (Ross, 1981), proverb interpretation (Benton, 1968), and indirect requests (Weylman, Brownell, Roman, & Gardner, 1989). The right hemisphere has also been implicated in the appreciation of humor. For example, Wapner, Hamby, and Gardner (1981) suggested that right hemisphere patients have difficulty in fully interpreting a joke's content. In addition, the right hemisphere is dominant for both the comprehension and expression of emotion in all modalities (Tucker, Luu, & Pribram, 1995).

Although the right hemisphere is clearly implicated in detection of irony and sarcasm, there are indications that the frontal lobes may also be involved in interpretation of sarcastic utterances. The frontal lobes have long been considered to play a special role in social cognition, with damage in this region affecting not only high-level cognitive functions but also social behavior (Adolphs, 1999; Eslinger, 1998) and personality (A. R. Damasio, 1994). Alexander, Benson, and Stuss (1989) suggested that damage to the frontal lobes area may impair analysis, planning, and monitoring of language. Understanding of sarcastic utterances by patients with prefrontal lesions has been directly tested in controlled experiments only once (McDonald & Pearce, 1996); the authors found that compared with healthy controls, these patients could not interpret sarcasm. In concordance with this, we also reported a deficit in interpretation of sarcasm in patients with prefrontal damage (Shamay et al., 2002). In these studies, however, patients with unilateral right and left frontal damage, or patients with lesions in nonfrontal brain regions, were not included.

Although the above-mentioned studies imply involvement of different brain regions in the comprehension of sarcasm, they do not indicate which areas are necessary for such comprehension. These studies fail to establish accurate localization because they do not examine the relative contribution of the side (right vs. left) and site (anterior vs. posterior) of lesions. This distinction is of high importance, as evidence from patients with frontal lobe damage suggests that the right frontal lobe is involved in nonliteral language functions (Alexander et al., 1989), humor appreciation (Shammi & Stuss, 1999), self-awareness (Stuss & Benson, 1986), and ToM (Stuss, Gallup, & Alexander, 2001), all of which are believed to be related to interpretation of sarcasm. It is thus possible that whereas either the right hemisphere or the frontal lobes play a role in mediating sarcasm, the right frontal lobe has a unique role in the understanding of sarcastic utterances.

The social communicative function of irony suggests a distinct role for ventromedial (VM) regions within the frontal lobes, as opposed to dorsolateral (DL) regions. Whereas DL prefrontal regions have been associated with executive functions, VM lesions have been shown to result in impaired social skills, such as social judgment (Eslinger & Damasio, 1985) and decision making (Bechara, Damasio, Tranel, & Anderson, 1998). Thus, if patients with lesions in subregions of the prefrontal cortex differ in their deficit in understanding sarcasm, this would suggest that specific areas within the prefrontal cortex are crucial to the mediation of comprehension of sarcastic utterances. To the best of our knowledge, no study to date has directly examined deficits in the interpretation of sarcasm in patients with limited focal lesions in distinct prefrontal and posterior regions of the brain or examined the contribution of asymmetry and exact localization of the lesion within the frontal lobes. The purpose of the present study was thus twofold: first, to examine the neural basis of understanding sarcasm, and second, to explore the relationship between deficits in the comprehension of sarcasm and social cognition. We therefore examined the relationships between performance on tasks that assess the understanding of sarcasm and performance on tasks that assess ToM (the "faux pas" task) and affect recognition (facial expression, affective prosody) in patients with well-defined localized brain lesions.

METHOD

Participants

Patients with well-defined, localized, acquired cortical lesions, who were referred for a cognitive assessment at the Cognitive Neurology Unit, were recruited for participation in this study. Etiology of lesions included brain contusions and hematomas following traumatic head injury ($n = 30$), brain tumors ($n = 7$), and cerebrovascular accident (CVA) ($n = 4$). All patients gave informed consent for participation in the study. Testing of participants required two meetings (1 hr each). Neurologic and neuropsychological screening were conducted in the first session, and the tasks assessing sarcasm, ToM, and recognition of affect were administered during the second session. Anatomical classification was based on current (within 6 months) magnetic resonance (MR) or computerized axial tomography (CT) data. For inclusion, lesions had to be localized to either frontal or non-frontal cortical regions. Frontal lesions included cases with gray and white matter lesions. Lesions extending to the basal ganglia were excluded. For patients with head injury, the acute neuroradiological studies were examined, and all patients with characteristics of diffuse axonal injury were excluded. Lesion location was classified as frontal (prefrontal cortex [PFC], $n = 25$) and posterior (posterior cortex [PC], $n = 16$) subgroups on the basis of the location of the lesion. Seventeen aged-matched healthy volunteers served as controls (healthy controls; HC).

The PFC group consisted of 12 patients with unilateral lesions (left hemisphere = 6, right hemisphere = 6) and 13 patients with bilateral lesions. The PC subgroup included 16 patients with unilateral lesions (left hemisphere = 9, right hemisphere = 7).

No patient had an aphasic disturbance. Testing and lesion localization were undertaken at least 6 months (average time: 19.34 [$SD = 16.32$] months) after the acute onset. All participants were free of history of significant alcohol or substance abuse, psychiatric disorder, or other illness affecting the central nervous system. All participants completed the Raven's Progressive Matrices (Raven, Court, & Raven, 1992) so that we could assess reasoning and obtain an estimate of general intellectual functioning. The following measures were used to evaluate the partici-

Table 1
Detailed Description of the Patients With Frontal Lesions


































Participant	Lesion site and etiology	Size of lesion ^a		Participant	Lesion site and etiology	Size of lesion ^a	
		Left	Right			Left	Right
1.	 Ventromedial + dorsolateral subarachnoid hematoma	1	0	12.	 Ventromedial + dorsolateral encephalomacia	16.00	17.00
2.	 Ventromedial contusion	0	.125	13.	 Ventromedial encephalomacia	0	2.00
3.	 Ventromedial contusion	0	1.38	14.	 Dorsolateral contusion	6.5	0
4.	 Dorsolateral hematoma	.31	4.00	15.	 Ventromedial + dorsolateral contusion	3.5	8.00
5.	 Ventromedial contusion	.25	.25	16.	 Dorsolateral aneurysm	0	.625
6.	 Dorsolateral meningioma	0	5	17.	 Ventromedial + dorsolateral meningioma	.75	0
7.	 Ventromedial + dorsolateral subarachnoid hematoma	7.5	4.75	18.	 Ventromedial contusion	8.25	2.5
8.	 Dorsolateral subarachnoid hematoma	0	2.00	19.	 Ventromedial contusion	2.6125	3.25
9.	 Ventromedial + dorsolateral contusion	6.00	12.5	20.	 Dorsolateral meningioma	0	2.5
10.	 Ventromedial contusion	1.00	3.125	21.	 Ventromedial contusion	7.5	.125
11.	 Ventromedial contusion	4	3.63	22.	 Dorsolateral hematoma	1	0

Table 1 (continued)

Participant	Lesion site and etiology	Size of lesion ^a		Participant	Lesion site and etiology	Size of lesion ^a	
		Left	Right			Left	Right
23.	 Ventromedial + dorsolateral craniectomy	15.25	16	33.	 Inferior parietal lobule meningioma	1	0
24.	 Ventromedial hematoma	0	8	34.	 Anterior to auditory region (area 22) subarachnoid hematoma	0.5	0
25.	 Ventromedial meningioma	14	16	35.	 Superior parietal lobule meningioma	2	0
26.	 Superior parietal lobule meningioma	2	0	36.	 Superior parietal lobule contusion	2	0
27.	 Inferior parietal lobule contusion	0	1.5	37.	 Inferior and superior parietal lobule CVA	5.5	0
28.	 Superior parietal lobule meningioma	7	0	38.	 Superior parietal lobule CVA	0	2
29.	 Inferior parietal lobule hematoma CVA	5	0	39.	 Inferior parietal lobule subarachnoid hematoma	2	0
30.	 Inferior parietal lobule subarachnoid hematoma	0.5	0	40.	 Infracalcaine (Area 19)	0	1.5
31.	 Inferior parietal lobule CVA	0	3.5	41.	 Inferior parietal lobule CVA	4.2	0
32.	 Inferior parietal lobule CVA	0	6.5				

Note. CVA = cerebrovascular accident.

^a See METHOD section (Lesion Analysis of the Patients With Prefrontal Damage) for calculation of lesion size.

pants' executive functions: The Wisconsin Card Sorting Test (WCST) and the fluency tests Verbal Fluency and Design Fluency.

Lesion Analysis of the Patients With Prefrontal Damage

We further analyzed the patients with prefrontal damage on the basis of visual quantitative evaluation of the MR and CT data. Two neuroradiologists blind to the study's hypotheses and the neuropsychological data carried out this analysis. The final rating was based on two evaluations of the same imaging data for each subject, which were performed in different sessions. Lesions were localized and transferred to templates following the method of H. Damasio and Damasio (1989). The lesions were also transcribed to computerized templates available on MRIcro (Rorden, 2004), a software program that allows viewing and exporting of brain images and identifying regions of interest. To assess the extent of the lesion, we used a semiquantitative 4-point scale (0 indicates *no lesions*, 1 indicates a *5-mm lesion*, 2 indicates a *10-mm lesion*, 3 indicates a *15-mm lesion*). The size of the lesion was quantified for each axial slice in which the lesion was evident, and an overall score for the lesion size was obtained by summing the scores for the separate slices. A separate score was derived for the left and right hemispheres in each slice (see Table 1).

Following this procedure, the patients with frontal pathology were further assigned to one of three lesion groups (see Table 1): VM (Brodmann areas: mesial 6, 8, and 9, 10, 11, 12, 24), DL (Brodmann areas: 44, 45, DL 8 and 9, and 46), and mixed lesions (VM and DL). There were 11 patients with VM lesions, 7 with DL lesions, and 7 with mixed lesions (see Table 1).

The PC group was also further divided into subgroups according to the posterior sectors of functional significance where cortical lesion was apparent: superior parietal lobule (SUP = Brodmann areas 7 and 5), inferior parietal lobule (INF = Brodmann areas 40 and 39), infracalcarine (Infra = Brodmann areas 18 and 19), and anterior to auditory region (Ant = Brodmann area 22). Classification of PC patients was to the following subgroups: SUP = 6, INF = 6, SUP-INF = 2, Infra = 1, and Ant = 1).

Tasks

Sarcasm

The ability to understand ironic meaning was assessed with a task devised by Ackerman (1981) and adapted to Hebrew by Lapidot, Most, Pik, and Schneider (1998). It consists of 8 brief stories presenting an interaction between two characters. At the end of each interaction, one of the characters makes a comment directed at the other character. Each story is presented in two versions: a sarcastic version and a neutral version (total of 16 stories, presented in randomized order). The stories were pre-recorded, and the task was administered by an examiner who sat next to the participant and activated the tape recorder.

The sarcastic utterances were spoken with sarcastic intonation, and the neutral utterances were spoken with neutral intonation. Whereas in the sarcastic version the literal meaning of the speaker's comment is positive but the speaker's true meaning is negative, in the neutral version both the literal meaning and the speaker's intended meaning are positive. The following are examples of each item type.

A Sarcastic Version Item

Joe came to work, and instead of beginning to work, he sat down to rest. His boss noticed his behavior and said, "Joe, don't work too hard!"

A Neutral Version Item

Joe came to work and immediately began to work. His boss noticed his behavior and said, "Joe, don't work too hard!"

Following each story, two questions were asked:

1. A factual question (assessing story comprehension): Did Joe work hard?
2. An attitude question (assessing comprehension of the true meaning of the speaker): Did the manager believe Joe was working hard?

An error in identifying sarcasm was scored only when the participant answered the factual question correctly but the attitude question incorrectly. To control for memory load and executive dysfunctions, we did not count errors in Question 2 if the participant also had an error in Question 1. The scores were based only on errors in the sarcasm items. Participants who made more than two errors in the neutral version items were excluded.

Social Cognition

Understanding ToM Recognition of Faux Pas

To determine whether impaired understanding of sarcasm is related to ToM, we used a test designed by Baron-Cohen, Jolliffe, Mortimore, and Robertson (1997) that evaluates the ability of participants to recognize social faux pas. A *faux pas* occurs when a speaker says something without considering that the listener might not want to hear it or might be hurt by what has been said (for an example, see Appendix). This task was selected on the basis of previous findings that individuals with Asperger syndrome could pass easier ToM tasks such as first- and second-order false belief tasks but were impaired on the Faux Pas task (Baron-Cohen et al., 1997; Shamay-Tsoory, Tomer, Yaniv, & Aharon-Peretz, 2002). This task is therefore considered as tapping a more advanced capacity to make inferences regarding another person's state of mind (Stone, Baron-Cohen, & Knight, 1998). Detection of faux pas requires both an understanding that there may be a difference between a speaker's knowledge state and that of the listener and an appreciation of the emotional impact of a statement on the listener (Baron-Cohen, O'Riordan, Stone, Jones, & Plaisted, 1999). A Hebrew version of the 20 Faux Pas stories was used to compare the patients' responses to those of the controls. Participants were given 10 stories in which a faux pas had occurred and 10 control stories (total of 20 stories). After hearing each story, the participant was asked ToM questions (tapping detection of faux pas) and control questions (tapping story comprehension). The score consisted of the total number of all errors (for both the faux pas items and the control items, see Appendix). Participants with more than two errors on the control items (indicating comprehension difficulties) were excluded. Participants used printed copies of the stories while listening to the story being read. They were permitted to look for answers to the questions in their copy.

Affect Recognition Through Prosody and Through Facial Expressions

To test whether the ability to interpret sarcastic utterances relates to the general ability to identify emotion, and to determine whether impaired understanding of sarcasm is related to processing of emotional stimuli, we used two tasks: recognition of facial expression and recognition of affective prosody. These tasks measure an overall ability to identify emotions on the basis of either visual or auditory stimuli. Both modalities were used to examine whether a difficulty in understanding sarcasm was related to a general deficit in identifying emotions, or more specifically, was related to the auditory modality.

Recognition of facial expression. The ability to recognize facial expressions was evaluated with a modified version of the test devised by Ekman and Friesen (1976). This task evaluates the ability of participants to identify emotions. We used 35 pictures exhibiting seven emotional states from this battery (anger, disgust, happiness, surprise, fear, sadness, and neutral), and we assessed facial recognition with the Ekman and Friesen scoring system. Participants were exposed to the pictures and instructed to state the emotion presented in the picture. The total numbers of facial expressions detected, as well as the specific emotion, were recorded.

Recognition of affective prosody. The affective prosody was evaluated with a Hebrew version of a task devised by Ross, Thompson, and Yenksy (1997). A spoken sentence constant in semantic content but varying among angry, sad, happy, surprised, disgusted, and fearful emotional tones was presented. The stimuli were prerecorded, and the task was administered by an examiner who sat next to the participant and operated the tape recorder. Participants were instructed to mark the exact affect conveyed in each sentence, on a multiple-choice form.

RESULTS

The Role of the PFC

The PFC, PC, and HC groups did not differ in age, education, and estimated overall level of intellectual functioning (as measured by the Raven's Progressive Matrices score). Patients with prefrontal lesions made more errors in identifying sarcasm than either the PC or HC groups. Means and standard deviations were as follows: PFC = 1.28 ($SD = 1.64$), PC = 0.19 ($SD = 0.4$), and HC = 0.11 ($SD = 0.33$). One-way analysis of variance (ANOVA) revealed significant differences between these groups, $F(2, 55) = 7.21, p < .002$, and the post hoc analysis indicated that the prefrontal patients were significantly different from the two other groups (Duncan, $p < .05$), but the PC and HC groups did not differ from each other (see Figure 1).

Because the number of errors was very low, indicating a potential floor effect in the data, we conducted additional analysis using a nonparametric test. First, we used the Kruskal-Wallis H test, which indicated a significant difference between group means, $\chi^2(2, N = 58) = 11.070, p < .004$. We then reconfirmed group differences by creating a new nominal variable for error frequencies. Participants were divided into two groups on the basis of their sarcasm scores: those who had one error or more and those who

had no errors at all. We then analyzed the difference in group frequencies using the chi-square test. Significant differences were found between the PFC, PC, and HC groups, $\chi^2(2, N = 58) = 9.212, p < .01$; between the PFC and PC groups, $\chi^2(1, N = 41) = 4.533, p < .033$; and between the PFC and HC groups, $\chi^2(2, N = 42) = 7.135, p < .008$; but not between the PC and the HC groups, $\chi^2(1, N = 33) = 0.313, ns$.

No correlation was found between the patients' performance on sarcasm tasks and the Raven Progressive Matrices scores, years of education, or the performance of tasks assessing executive functioning (WCST, Verbal Fluency, Design Fluency), indicating that the observed impairment in the performance of the sarcasm task is independent of overall intellectual ability, executive functions, and formal education.

The Role of the Right PFC

The performance of the sarcasm comprehension task by patients with unilateral lesions and the HC group is summarized in Figure 2. Patients with right prefrontal lesions made more errors in identifying sarcasm than did patients with either left PFC or right and left PC lesions and the HC group. Means and standard deviations were as follows: right PFC = 2.00 ($SD = 1.78$), left PFC = 0.833 ($SD = 1.6$), bilateral PFC = 1.15 ($SD = 1.6$), right PC = 0.285 ($SD = 0.48$), left PC = 0.11 ($SD = 0.33$), and HC = 0.11 ($SD = 0.33$). A one-way ANOVA revealed a significant overall effect, $F(5, 52) = 3.668, p < .006$. Post hoc analysis indicated that the patients with the right prefrontal lesions were significantly different from those with left frontal, right posterior, and left PC lesions and from HCs (Duncan, $p < .05$). The patients with bilateral prefrontal lesions did not differ from the right prefrontal group.

The differences between groups was reconfirmed by means of the Kruskal-Wallis H , $\chi^2(5, N = 58) = 15.481, p < .008$. Analysis

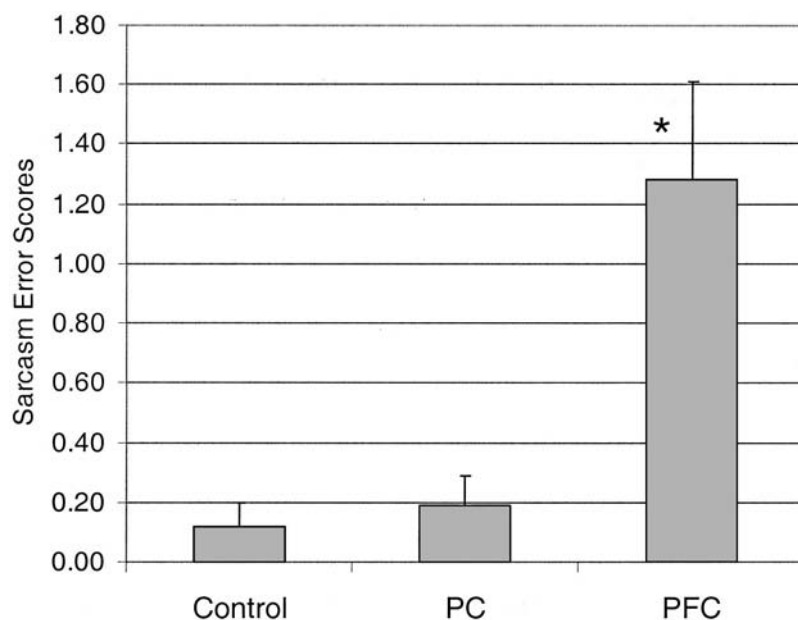


Figure 1. Mean sarcasm error scores (error bars represent standard error) in patients with posterior (PC) and prefrontal (PFC) lesions and in healthy controls. Post hoc analysis: PFC was significantly different from healthy controls and PC ($*p < .05$).

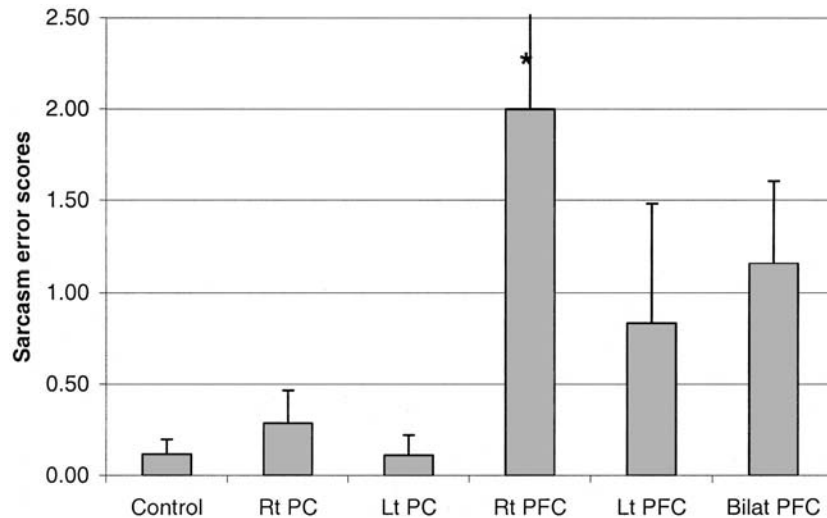


Figure 2. Mean sarcasm error scores (error bars represent standard error) in patients with unilateral lesions. Post hoc analysis: Right PFC was significantly different from left PFC, right PC, left PC, and controls ($*p < .05$). Rt = right; PC = posterior cortex; Lt = left; PFC = prefrontal cortex; Bilat = bilateral.

of error frequencies using chi-square indicated significant differences between all groups, $\chi^2(5, N = 58) = 13.709, p < .018$. In addition, the right prefrontal lesion group was significantly different from the HCs, $\chi^2(1, N = 23) = 10.729, p < .001$; right posterior group, $\chi^2(1, N = 13) = 3.899, p < .048$; and left posterior group, $\chi^2(1, N = 15) = 7.824, p < .005$, but not from the bilateral frontal group, $\chi^2(1, N = 19) = 2.328, ns$. The bilateral PFC patients were significantly different from the HCs, $\chi^2(1, N = 30) = 4.455, p < .053$. The rest of the groups were not significantly different from each other.

A one-way ANOVA of the performance of all the right hemisphere-lesioned patients (right PFC + right PC) versus the left

hemisphere-lesioned patients (left PFC + left PC) indicated no significant effect, $F(1, 27) = 1.95, ns$.

The Role of the Right VM PFC

Patients with VM lesions made more errors in identifying sarcasm than did either patients with PC lesions or HCs. Means and standard deviations were as follows: VM = 1.45 ($SD = 1.4$); DL = 0.857 ($SD = 1.86$); MIX = 1.42 ($SD = 1.9$); PC = 0.19 ($SD = 0.4$); and HCs = 0.11 ($SD = 0.33$). A one-way ANOVA of the prefrontal lesion subgroups (VM, DL, MIX, PC, and HC) was conducted to examine the differential effect of lesions in specific regions within the PFC, $F(4, 53) = 3.91, p = .007$. As Figure 3

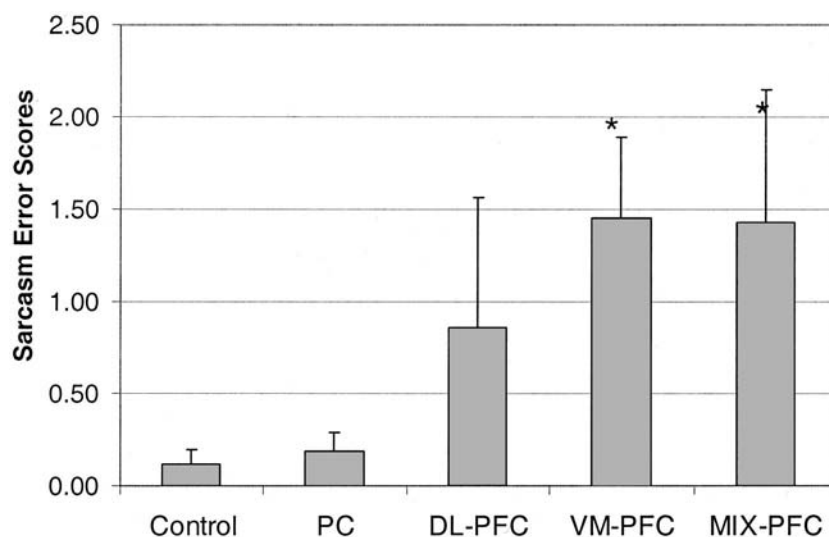


Figure 3. Mean sarcasm error scores (error bars represent standard error) in patients with lesions limited to subregions of the prefrontal cortex (PFC), compared with posterior cortex (PC) lesion patients and healthy controls ($*p < .05$). VM = ventromedial PFC; DL = dorsolateral PFC; MIX = mixed DL and VM lesions.

shows, post hoc analysis revealed that VM and the MIX groups, but not the DL group, were significantly different from patients with PC lesions and the HC groups (Duncan, $p < .05$). The differences between groups was confirmed with the Kruskal–Wallis H , $\chi^2(4, N = 58) = 13.709, p < .008$. Analysis of error frequencies using chi-square indicated significant differences between all groups, $\chi^2(4, N = 58) = 11.789, p < .019$. In addition, the VM group was significantly different from the HCs, $\chi^2(1, N = 28) = 8.239, p < .004$, and from the PC lesion group, $\chi^2(1, N = 27) = 5.632, p < .018$, but not from the MIX group, $\chi^2(1, N = 18) = 0.076, ns$. The MIX group was also significantly different from the HCs, $\chi^2(1, N = 24) = 5.445, p < .020$. The rest of the groups were not significantly different from each other.

We conducted supplementary analyses to investigate the effects of site and extent of lesions within the patient groups on performance on the sarcasm task. Patients with PFC lesions had overall larger lesions than did those with PC lesions. Means and standard deviations were as follows: PFC = 9.11 ($SD = 10.2$); PC = 2.78 ($SD = 2.11$). A one-way ANOVA of subgroups' size of lesions was conducted to examine the difference in size of lesions between subgroups (VM, DL, MIX, and the PC group). The difference in sizes of lesions was significant, $F(3, 37) = 8.655, p = .001$, and a post hoc analysis revealed that the MIX group had significantly larger lesions than the other subgroup (Scheffé, $p < .05$). All other groups did not differ from each other. However, to test the relation between lesion size and performance on the sarcasm task, we conducted a correlation analysis. This analysis revealed that for all patients, lesion size did not correlate with the sarcasm scores ($r = -.058, ns$), indicating that the lesion size could not account for the deficits in sarcasm. To identify the most critical lesion associated with the most severe deficit in understanding sarcastic utterances, we further analyzed the lesions of the participants who had the

lowest sarcasm scores (one standard deviation below all participants' mean, $n = 16$) and compared them with the participants who had the intact sarcasm scores ($n = 25$).

The contribution of the size of the lesion to the deficit in sarcasm was examined first by comparing overall lesion size between the impaired patients and all the nonimpaired patients with PFC lesions. The two groups did not differ in lesion size, $t(39) = 0.228, ns$, indicating that the deficit in understanding sarcasm could not be attributed to the lesion size alone.

We then examined the localization and extent of the lesions of the most severely impaired patients. The group of patients with the lowest sarcasm score consisted of 16 patients, 13 with PFC damage and 3 with PC damage: 8 had damage in the VM region, 2 had damage restricted to the DL, 3 had mixed damage (encompassing both VM and DL areas), 1 had a right INF damage, 1 had a SUP damage, and 1 had a INF-SUP damage. The nonimpaired group consisted of 12 patients with PFC damage (6 DL, 3 VM, and 3 MIX) and 13 patients with PC damage (5 INF, 5 SUP, 1 SUP-INF, 1 Ant, and 1 Infra). We then examined whether the degree of deficit in sarcasm was related to the extent of damage within the VM region and whether the side of lesion within that region was an important factor. To examine this, we calculated the overall size of the lesion for each patient in six separate regions: left and right VM area, left and right DL PFC area, and right and left PC area (see Figure 4).

We then compared the sizes of lesions in these regions in the impaired and nonimpaired groups by conducting a multivariate repeated measure ANOVA. Although both the overall effect of lesion size (Hotelling's trace; $F = 2.09, p = .089$) and the interaction with the group (impaired vs. nonimpaired; Hotelling's trace; $F = 1.2, p = .320$) were not significant, the tests of within-subjects contrasts indicated that in the impaired group, the

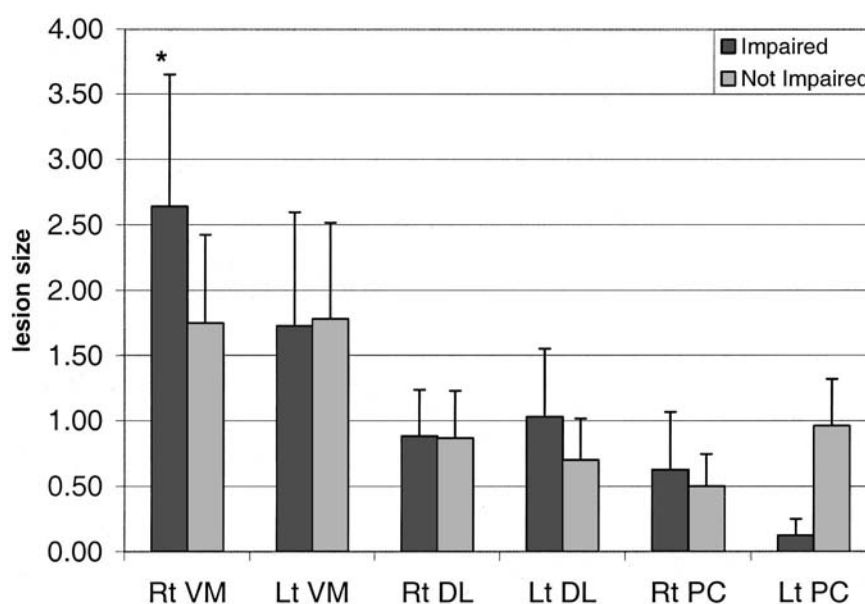


Figure 4. Average lesion sizes (error bars represent standard error) in the prefrontal cortex and posterior frontal cortex (PC) subregions. Rt = right; VM = ventromedial; Lt = left; DL = dorsolateral. In the impaired group, the right VM area lesion is significantly larger than the lesions in either the left VM, right DL, and left PC regions, but not different from the left DL ($*p < .05$).

lesions in the right VM area were significantly larger than the lesions in the left VM, $F(1, 15) = 5.95, p = .028$; right DL, $F(1, 15) = 5.56, p = .032$; and left PC, $F(1, 15) = 5.83, p = .029$, regions (but not significantly different from the left DL and right PC). However, in the unimpaired group, the tests of within-subjects contrasts indicated no significant differences in lesion size between any of the subgroups.

In addition, the link between the extent of lesion within the right hemisphere, frontal lobes and impaired comprehension of sarcasm was further illuminated by a correlation analysis between sarcasm scores and lesion sizes in the right and left VM and in the right and left DL. The sarcasm scores that correlated significantly with lesion sizes were for the right VM ($r = .266, p = .046$) and the right DL ($r = .306, p = .026$), but not with the left VM ($r = .099, ns$) and left DL ($r = .044, ns$).

To separate the effect of total lesion size from the effect of lesion size in a specific region, we conducted a one-tailed partial correlation, with the overall size of lesion serving as a covariate. Results indicated that the highest correlation (albeit only marginally significant) was the one between sarcasm scores and right VM lesion size ($r = .253, df = 38, p = .057$). Correlations between sarcasm scores and lesions in the left VM ($r = .06, df = 38, ns$), the right DL ($r = .103, df = 38, ns$), and the left DL ($r = -.061, df = 38, ns$) were not significant.

The contribution of the right VM was further emphasized by a graphic superimposition of the lesions of the impaired patients. This analysis revealed that although the size of the lesions differed widely, in 10 of these 13 patients the right VM region was involved (see Figure 5).

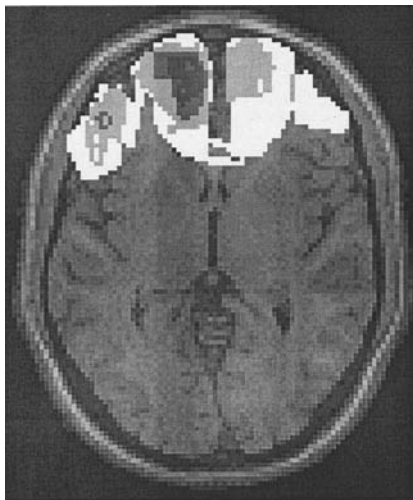


Figure 5. Lesions associated with impaired ability to interpret sarcasm. Reconstruction of the prefrontal cortex lesions in 13 patients with the most impaired sarcasm scores. Superimposition of lesions indicated that in this group, the lesion in the right ventromedial area was significantly larger than the lesions in either the left ventromedial or right dorsolateral regions (but not significantly different from the left dorsolateral). Note that in the picture, as in imaging scans, left is right.

The Relationship Between ToM, Affect Recognition, and Sarcasm

Separate ANOVAs (with Duncan post hoc analysis where warranted) were conducted for ToM and for affect recognition. These analyses revealed that the prefrontal group performed significantly less well than the posterior and control participants on the Faux Pas task, $F(2, 55) = 6.39, p = .003$, but not on the total number of errors in identification of affective prosody, $F(2, 55) = 2.57, ns$, and facial expression, $F(2, 55) = 2.21, ns$. However, a separate ANOVA of the performance of patients with unilateral right versus unilateral left lesions revealed that patients with lesions restricted to the right hemisphere performed more poorly on tasks of affect recognition, making significantly more errors when asked to identify affective prosody, $F(1, 27) = 14.63, p = .001$, and facial expression, $F(1, 27) = 5.96, p = .021$. The performance on both tasks of affect recognition (facial recognition and prosody) was positively correlated for all the participants ($r = .26, p = .023$).

There were no significant differences in performance on the Faux Pas task between right and left hemisphere-damaged patients. A significant overall effect was revealed when the performance of the Faux Pas task by patients with unilateral lesions was compared with that of the HCs: one-way ANOVA, $F(5, 45) = 3.307, p = .013$. Post hoc analysis indicated that the patients with the right prefrontal lesions were significantly different from those with left frontal, right posterior, and left posterior lesions and from the HCs (Duncan, $p < .05$).

A one-way ANOVA of the prefrontal lesion subgroups (VM, DL, and MIX) was conducted to examine the differential effect on Faux Pas of lesions in specific regions within the PFC, $F(4, 46) = 4.90, p = .002$. Post hoc analysis revealed that only the VM group was significantly different from the HC group (Scheffé, $p < .05$). The DL, MIX, and PC groups did not differ from each other.

The relationships between sarcasm and social cognition (ToM, affect recognition) were examined with a correlation analysis. To examine the pattern of correlations between sarcasm scores and the performance in the facial expression and affective prosody tasks, we averaged the two variables into one variable that reflected performance in affective processing. For the entire sample, comprehension of sarcasm correlated moderately but significantly with the Faux Pas scores ($r = .247, p = .039$) and affective processing ($r = .307, p = .011$). No significant correlations were found when the different emotions (i.e., anger, happiness) were analyzed separately.

DISCUSSION

The present study offers findings regarding the neurobiology of comprehension of sarcasm and the cognitive processes underlying it. First, in the task that assesses understanding of sarcastic utterances, participants with prefrontal damage showed impaired performance, whereas participants with posterior damage and HCs showed a preserved performance. Within the frontal lobe group, right prefrontal damage, and particularly damage incorporating the right VM region, was associated with the most profound deficit in understanding sarcasm. Second, although prefrontal damage was associated with deficits in ToM and right hemisphere damage was associated with deficits in the ability to identify emotions, both abilities were related to the ability to understand sarcastic utterances.

The significant difference in sarcasm scores between patients with prefrontal and posterior cortical lesions is consistent with

previous findings regarding the role of the frontal lobes in mediating pragmatic language processes (Alexander et al., 1989), irony, and sarcasm (McDonald & Pearce, 1996; Shamay et al., 2002). Both the right hemisphere and the frontal lobes appear to contribute to processes of social cognition (Adolphs, 1999). However, the specific role of the right frontal lobe in understanding sarcasm has not been described before.

Given the emotional and social communicative function of sarcastic utterances, it is only to be expected that its interpretation would be mediated by brain areas specialized in affective processing and social cognition. As noted above, the right frontal lobe has been implicated in nonliteral language functions (Alexander et al., 1989), humor appreciation (Shammi & Stuss, 1999), and self-awareness (Stuss & Benson, 1986). It has been previously suggested that the right and the left hemispheres have separate contributions to communication, the left hemisphere's role being propositional and symbolic and the right hemisphere's role being emotional (Bloom, Borod, Obler, & Gerstman, 1993; Buck, 1995).

A large body of literature has implicated the right hemisphere in the processing of emotional stimuli. Lesion studies have found a right hemisphere involvement in judgment of other people's emotional states from viewing their faces (Adolphs, Damasio, Tranel, Cooper, & Damasio, 2000) and from listening to their emotional tone (Ross et al., 1997). In the present study, right hemisphere damage was associated with impaired recognition of facial expression and affective prosody, and these abilities were related to the ability to detect sarcasm. The results of the present study confirm yet again these reports and add that emotional processing occurring in the right hemisphere contributes to the ability to understand sarcastic utterances.

Winner et al. (1998) suggested that the right hemisphere may play an important role in mediating the ability to understand sarcastic utterances. Surprisingly, we did not find any overall differences in the performance of the sarcasm task between patients with right and left hemisphere lesions. Participants with right posterior damage were as intact as HCs. However, the exact location of the lesion within the right hemisphere was not reported in earlier studies that found a deficit in the understanding of sarcasm among patients with right hemisphere damage. It is possible that the lesions reported in the work of Winner et al. (1998) were localized to the right PFC, or that within a mixed group of patients with right hemisphere damage, the difficulty in comprehension of sarcasm was more pronounced in those with prefrontal, compared with posterior, right hemisphere lesions.

Whereas the right hemisphere has been implicated in affect recognition, the PFCs have been implicated in more complex social cognition processes (Adolphs, 1999). In the process of interpreting sarcastic utterances, the individual is required to understand the speaker's feelings, intentions, and perspective. In the present study, patients with prefrontal damage showed impaired ability to identify social faux pas, indicating deficits in ToM. The impairment in ToM was correlated with the deficit in understanding sarcasm. It has been suggested that understanding irony requires the ability to grasp the speaker's actual beliefs and the speaker's belief about the listener's belief (Winner, 1988). Damage to the frontal lobes, particularly to the orbitofrontal-VM cortex, results in impaired social behavior in primates (Rolls, 2000) and humans (A. R. Damasio, 1994). The VM has been previously linked to empathy (Eslinger, 1998; Shamay-Tsoory, Tomer, Berger, & Aharon-Peretz, 2003) and ToM, in both imaging studies (Baron-Cohen et al., 1994; Fletcher et al., 1995; Gallagher et

al., 2000; Goel, Grafman, Sadato, & Hallett, 1995) and lesion studies (Rowe, Bullock, Polkey, & Morris, 2001; Stone et al., 1998; Stuss et al., 2000).

VM lesions have been shown to disrupt social and emotional behavior. Common sequelae of orbitofrontal damage include lack of affect and social irresponsibility (Bechara, Tranel, Damasio, & Damasio, 1996). There are also complex deficits in reasoning, judgment, and creativity (Benton, 1968; Eslinger & Damasio, 1985; Mesulam, 1985). Recent neuropsychological studies by Damasio and colleagues found that patients with lesions of the VM manifest impairments in real-life decision making, but other intellectual abilities remain preserved (A. R. Damasio, 1994). Bechara and colleagues developed a gambling task to model certain key aspects of real-life decision making (Bechara et al., 1996). They found that patients with VM lesions were significantly impaired on this gambling paradigm, being overly guided by immediate prospects at the expense of potential long-term consequences. These authors thus conceived of the VM PFC as part of a large-scale system mediating decision making in a process that also requires integration of cognition and emotions. In concordance with this, on the basis of functional imaging, Elliott, Dolan, and Frith (2000) suggested that activity in the VM is most likely to be observed when there is insufficient information available to determine the appropriate course of action. In these circumstances, the VM cortices are more likely to be activated when the problem of what to do next is best solved by integrating information regarding the consequences of the stimuli (Elliott et al., 2000). Taken together, these functions may well be considered as basic components of higher social communicative behaviors, such as processing the meaning of a sarcastic utterance. It might therefore be speculated that the process of understanding sarcasm involves decision making regarding the meanings of the sarcastic utterance. We suggest that in order to reject the literal meaning of the utterance, the listener must comprehend the speaker's attitude, intentions, and emotional state and then consider alternative explanations. The listener has to integrate all the components embedded in a given social interaction and make a decision regarding the true meaning of the speaker. Damage to the VM impairs this ability and produces deficits in understanding sarcasm.

Is another interpretation possible? One might argue that the prefrontal patients' failure to understand sarcastic utterances could be accounted for by a more general executive disorder. Shallice and Burgess (1996) described a model for executive functioning involving two sources of action control. One is for well-learned habitual patterns that are triggered automatically for carrying out routine tasks, and another is an attentional controller capable of overriding habitual responses for dealing with novel situations. The latter is mediated by the frontal lobes and enables executive processes. Impairment to this system may lead to automatic responses to verbal stimuli and stimulus-boundedness to a concrete meaning of the sentence. Patients with prefrontal damage may therefore be responding to the concrete meaning of the sentence (the literal meaning), showing a tendency to perseverate and being incapable of considering alternative meanings. However, we believe that the deficit in understanding sarcasm observed in the present study cannot be ascribed to an executive disorder, because participants' performance in the sarcasm task was not related to their performance in tasks assessing executive functions (WCST, fluency tests). Rather, such a deficit may be due to the specific challenge posed by sarcasm. The present results indicate that understanding sarcasm requires both the ability to understand the speaker's belief about the listener's belief and the ability to identify

emotions. Moreover, it has been previously demonstrated that processes of social cognition such as ToM are doubly dissociable from other executive processes that rely on the PFC (Blair & Cipolotti, 2000; Fine, Lumsden, & Blair, 2001), particularly the DL sector of the PFC (Bechara, Damasio, Tranel, & Anderson, 1998). Thus, it is possible that although processes of interpretation of sarcasm are independent from executive function, they require social cognition such as ToM and affect recognition.

The present results also bear indirectly on the issue of the relation between literal and nonliteral language comprehension in understanding irony. Although some theorists have argued that in the process of understanding sarcasm, the listener first interprets the literal meaning of the sentence and then reinterprets it according to the context and the speaker's meaning (Grice, 1975), others have emphasized the importance of the speaker's attitude and suggested that the speaker's meaning might be accessed without full processing of the literal meaning and its incongruity (e.g., Gibbs, 1986; Long & Graesser, 1988). The current results are consistent with both psycholinguistic models of sarcasm. On one hand, the patients interpreted the literal meaning as the true meaning, indicating that they did process the literal meaning. The sarcastic stories were more difficult to understand than the neutral stories of exactly the same form. This is in agreement with the suggestion that both literal and nonliteral meaning are obligatorily processed (Dews & Winner, 1999). On the other hand, the patients' difficulty in understanding sarcasm was related to their impaired social cognition. The patients who failed to identify the speaker's attitude and showed impaired social cognition tended also to misinterpret the sarcastic utterance, indicating that the attitude of the speaker is also critical for the interpretation of sarcasm.

In addition to the localization of the lesion within the frontal lobe, our analyses have also highlighted the importance of the lesion size within subregions of the frontal lobe: Regardless of overall lesion size, the extent of the lesion in the right VM was found to be significantly related to the performance in the sarcasm task. Nevertheless, we do not propose that understanding sarcasm is strictly localized to the right VM. Rather, on the basis of our current findings, we propose that the ability to process sarcastic utterances is mediated by a neural network, in which the right VM plays a central role. The proposed network operates in three successive stages, each mediated by different neuroanatomical areas. First, the literal meaning of the utterance is interpreted in left hemisphere language cortices. Hence, at the beginning of the process, judgment of a literal and a nonliteral meaning of a sentence involves a common neural network. Second, the intentional, social, and emotional context is processed in the frontal lobes and the right hemisphere, correspondingly. At this stage, the contradiction between the literal meaning and the social emotional context is identified. Finally, to derive the true meaning of the utterance, the listener then has to integrate the literal meaning along with the social and emotional knowledge of the particular situation and previous situations and make a decision regarding the true meaning. The present results indicate that the right VM PFC plays a critical role in this stage. Each of the above components has some specialization and plays a role in understanding sarcasm. The right hemisphere contributes to processing of the affective information conveyed, and the prefrontal lobes contribute to processing of the speaker's perspective. We suggest that these distinct processes overlap and are integrated by the right VM region of the PFC, allowing correct understanding of sarcastic utterances. Indeed, the region most lesioned in the group of

patients with the most severe deficit in sarcasm was the VM. Functional imaging studies, designed to examine the proposed network, will help in evaluating this model.

References

- Ackerman, B. (1981). Young children's understanding of a false utterance. *Developmental Psychology, 31*, 472–480.
- Adolphs, R. (1999). Social cognition and the human brain. *Trends in Cognitive Science, 3*, 469–479.
- Adolphs, R., Damasio, H., Tranel, D., Cooper, G., & Damasio, A. R. (2000). A role for somatosensory cortices in the visual recognition of emotion as revealed by three-dimensional lesion mapping. *Journal of Neuroscience, 20*, 2683–2690.
- Alexander, M. P., Benson, F. D., & Stuss, D. T. (1989). Frontal lobe and language. *Brain and Language, 37*, 656–691.
- Baron-Cohen, S., Jolliffe, T., Mortimore, C., & Robertson, M. (1997). Another advanced test of theory of mind: Evidence from very high functioning adults with autism or Asperger syndrome. *Journal of Child Psychology and Psychiatry, 38*, 813–822.
- Baron-Cohen, S., O'Riordan, M., Stone, V., Jones, R., & Plaisted, K. (1999). Recognition of faux pas by normally developing children and children with Asperger syndrome or high-functioning autism. *Journal of Autism and Developmental Disorders, 29*, 407–418.
- Baron-Cohen, S., Ring, H., Moriarty, J., Schmitz, B., Costa, D., & Ell, P. (1994). Recognition of mental state terms. Clinical findings in children with autism and a functional neuroimaging study of normal adults. *British Journal of Psychiatry, 165*, 640–649.
- Bechara, A., Damasio, H., Tranel, D., & Anderson, S. W. (1998). Dissociation of working memory from decision making within the human prefrontal cortex. *Journal of Neuroscience, 118*, 428–437.
- Bechara, A., Tranel, D., Damasio, H., & Damasio, A. R. (1996). Failure to respond autonomically to anticipated future outcomes following damage to prefrontal cortex. *Cerebral Cortex, 6*, 215–225.
- Benton, A. L. (1968). Differential behavioral effects of frontal lobe disease. *Neuropsychologia, 6*, 53–60.
- Blair, R. J. R., & Cipolotti, L. (2000). Impaired social response reversal: A case of "acquired sociopathy." *Brain, 123*, 1122–1141.
- Bloom, R. L., Borod, J. C., Obler, L. K., & Gerstman, L. J. (1993). Suppression and facilitation of pragmatic performance: Effects of emotional content on discourse following right and left brain damage. *Journal of Speech and Hearing Research, 36*, 1227–1235.
- Brown, P., & Levinson, S. (1978). *Politeness: Some universals in language use*. Cambridge, England: Cambridge University Press.
- Brownell, H. H., Simpson, T. L., Bihrl, A. M., Potter, H. H., & Gardner, H. (1990). Appreciation of metaphoric alternative word meanings by left and right brain-damaged patients. *Neuropsychologia, 28*, 375–383.
- Buck, R. (1995). The neuropsychology of communication: Spontaneous and symbolic aspects. *Journal of Pragmatics, 22*, 265–278.
- Caplan, R., & Dapretto, M. (2001). Making sense during conversation: An fMRI study. *NeuroReport, 12*, 3625–3632.
- Damasio, A. R. (1994). *Descartes' error: Emotion, reason and the human brain*. New York: Avon Books.
- Damasio, H., & Damasio, A. (1989). *Lesion analysis in neuropsychology*. New York: Oxford University Press.
- Dennis, M., Purvis, K., Barnes, M. A., Wilkinson, M., & Winner, E. (2001). Understanding of literal truth, ironic criticism, and deceptive praise following childhood head injury. *Brain and Language, 78*, 1–16.
- Dews, S., & Winner, E. (1995). Muting the meaning: A social function of irony. *Metaphor and Symbolic Activity, 10*, 3–18.
- Dews, S., & Winner, E. (1997). Attributing meaning to deliberately false utterances: The case of irony. In C. Mandell & A. McCabe (Eds.), *The problem of meaning: Behavioral and cognitive perspectives* (pp. 377–414). New York: Elsevier Science.

- Dews, S., & Winner, E. (1999). Obligatory processing of literal and non-literal meaning of verbal irony. *Journal of Pragmatics*, *31*, 1579–1599.
- Ekman, P., & Friesen, W. V. (1976). *Pictures of facial affect*. Palo Alto, CA: Consulting Psychologists Press.
- Elliott, R., Dolan, R. J., & Frith, C. D. (2000). Dissociable functions in the medial and lateral orbitofrontal cortex: Evidence from human neuroimaging studies. *Cerebral Cortex*, *10*, 308–317.
- Eslinger, P. J. (1998). Neurological and neuropsychological bases of empathy. *European Neurology*, *39*, 193–199.
- Eslinger, P. J., & Damasio, A. R. (1985). Severe disturbance of higher cognition after bilateral frontal lobe ablations: Patient EVR. *Neurology*, *35*, 1731–1741.
- Fine, C., Lumsden, J., & Blair, R. J. (2001). Dissociation between 'theory of mind' and executive functions in a patient with early left amygdala damage. *Brain*, *124*(Pt. 2), 287–298.
- Fletcher, P. C., Happe, F., Frith, U., Baker, S. C., Dolan, R. J., Frackowiak, R. S., & Frith, C. D. (1995). Other minds in the brain: A functional imaging study of "theory of mind" in story comprehension. *Cognition*, *57*, 109–128.
- Gallagher, H. L., Happe, F., Brunswick, N., Fletcher, P. C., Frith, U., & Frith, C. D. (2000). Reading the mind in cartoons and stories: An fMRI study of 'theory of mind' in verbal and nonverbal tasks. *Neuropsychologia*, *38*, 11–21.
- Gibbs, R. W. (1986). On the psycholinguistics of sarcasm. *Journal of Experimental Psychology: General*, *115*, 3–15.
- Goel, V., Grafman, J., Sadato, N., & Hallett, M. (1995). Modeling other minds. *NeuroReport*, *6*, 1741–1746.
- Grice, H. P. (1975). Logic of conversation. In P. Cole & J. L. Morgan (Eds.), *Syntax and semantics: Speech acts* (Vol. 3, pp. 41–58). New York: Academic Press.
- Grice, H. P. (1978). Further notes on logic and conversation. In P. Cole (Ed.), *Syntax and semantics: Pragmatics* (Vol. 3, pp. 113–127). New York: Academic Press.
- Happe, F. G. (1993). Communicative competence and theory of mind in autism: A test of relevance theory. *Cognition*, *48*, 101–119.
- Kaplan, J. A., Brownell, H. H., Jacobs, J. R., & Gardner, H. (1990). The effects of right hemisphere damage on the pragmatic interpretation of conversational remarks. *Brain and Language*, *38*, 315–333.
- Lapidot, M., Most, T., Pik, E., & Schneider, R. (1998, August). *Effects of prosodic information and context on perception of irony by children and adults*. Paper presented at the 24th World Congress of the International Association of Logopedics and Phoniatrics, Amsterdam, the Netherlands.
- Long, D. L., & Graesser, A. C. (1988). Wit and humor in discourse processing. *Discourse Processes*, *11*, 35–60.
- McDonald, S. (1999). Exploring the process of inference generation in sarcasm: A review of normal and clinical studies. *Brain and Language*, *68*, 486–506.
- McDonald, S., & Pearce, S. (1996). Clinical insights into pragmatic theory: Frontal lobe deficit and sarcasm. *Brain and Language*, *53*, 81–104.
- Mesulam, M. M. (1985). *Principles of behavioral neurology*. Philadelphia: F. A. Davis.
- Raven, J. C., Court, J. H., & Raven, J. (1992). *Manual for Raven's Progressive Matrices and Vocabulary Scales*. Oxford, England: Oxford Psychologists Press.
- Rehak, A., Kaplan, J. A., & Gardner, H. (1992). Sensitivity to conversational deviance in right-hemisphere-damaged patients. *Brain and Language*, *42*, 203–217.
- Rolls, E. T. (2000). The orbitofrontal cortex and reward. *Cerebral Cortex*, *10*, 284–294.
- Rorden, C. (2004). MRIcro [Computer software]. Retrieved May 14, 2003, from <http://people.cas.sc.edu/rorden/>
- Ross, E. D. (1981). The aprosodias. Functional-anatomic organization of the affective components of language in the right hemisphere. *Archives in Neurology*, *38*, 561–569.
- Ross, E. D., Thompson, R. D., & Yenkosky, J. (1997). Lateralization of affective prosody in brain and callosal integration of hemispheric language function. *Brain and Language*, *56*, 27–54.
- Rowe, A. D., Bullock, P. R., Polkey, C. E., & Morris, R. G. (2001). "Theory of mind" impairments and their relationship to executive functioning following frontal lobe excisions. *Brain*, *124*(Pt. 3), 600–616.
- Shallice, T., & Burgess, P. (1996). The domain of supervisory processes and temporal organization of behaviour. *Philosophical Transactions of the Royal Society of London, Series B: Biological Science*, *251*, 1405–1412.
- Shamay, S. G., Tomer, R., & Aharon-Peretz, J. (2002). Deficit in understanding sarcasm in patients with prefrontal lesion is related to impaired empathic ability. *Brain and Cognition*, *48*(2–3), 558–563.
- Shamay-Tsoory, S. G., Tomer, R., Berger, B. D., & Aharon-Peretz, J. (2003). Characterization of empathy deficits following prefrontal brain damage: The role of the right ventromedial prefrontal cortex. *Journal of Cognitive Neuroscience*, *15*, 324–337.
- Shamay-Tsoory, S. G., Tomer, R., Yaniv, S., & Aharon-Peretz, J. (2002). Empathy deficits in Asperger syndrome: A cognitive profile. *Neuro-Case*, *8*, 245–252.
- Shammi, P., & Stuss, D. T. (1999). Humour appreciation: A role of the right frontal lobe. *Brain*, *122*(Pt. 4), 657–666.
- Sperber, D., & Wilson, D. (1981). Irony and the use of mention distinction. In P. Cole (Ed.), *Radical pragmatics* (pp. 295–318). New York: Academic Press.
- Sperber, D., & Wilson, D. (1986). *Relevance: Communication and cognition*. Oxford, England: Basil Blackwell.
- Stone, V. E., Baron-Cohen, S., & Knight, R. T. (1998). Frontal lobe contributions to theory of mind. *Journal of Cognitive Neuroscience*, *10*, 640–656.
- Stuss, D. T., & Benson, D. F. (1986). *The frontal lobes*. New York: Raven Press.
- Stuss, D. T., Gallup, G. G., & Alexander, M. P. (2001). The frontal lobes are necessary for 'theory of mind.' *Brain*, *124*, 279–286.
- Sullivan, K., Winner, E., & Hopfied, N. (1995). How children tell a lie from a joke: The role of second-order mental state attributions. *British Journal of Developmental Psychology*, *13*, 191–204.
- Tucker, D. M., Luu, P., & Pribram, K. H. (1995). Social and emotional self-regulation. In J. Grafman, K. J. Holyoak, & F. Boller (Eds.), *Annals of the New York Academy of Sciences: Vol. 769. Structure and function of the human prefrontal cortex* (pp. 213–239). New York: New York Academy of Sciences.
- Wapner, W., Hamby, S., & Gardner, H. (1981). The role of the right hemisphere in the apprehension of complex linguistic materials. *Brain and Language*, *14*, 15–33.
- Weylman, S. T., Brownell, H. H., Roman, M., & Gardner, H. (1989). Appreciation of indirect requests by left- and right-brain-damaged patients: The effects of verbal context and conventionality of wording. *Brain and Language*, *36*, 580–591.
- Winner, E. (1988). *The point of words: Children's understanding of metaphor and irony*. Cambridge, MA: Harvard University Press.
- Winner, E., Brownell, H., Happe, F., Blum, A., & Pincus, D. (1998). Distinguishing lies from jokes: Theory of mind deficit and discourse interpretation in right hemisphere brain damage patients. *Brain and Language*, *62*, 89–106.
- Winner, E., & Leekam, S. (1991). Distinguishing irony from deception: Understanding the speaker's second order intention. *British Journal of Developmental Psychology*, *9*, 257–270.

Appendix

Irony and Faux Pas Tasks

Irony

A sarcastic version item: Joe came to work, and instead of beginning to work, he sat down to rest. His boss noticed his behavior and said, "Joe, don't work too hard!"

A neutral version item: Joe came to work and immediately began to work. His boss noticed his behavior and said, "Joe, don't work too hard!"

Following each story, two questions were asked:

1. A factual question (assessing story comprehension): Did Joe work hard?
2. An attitude question (assessing comprehension of the true meaning of the speaker): Did the manager believe Joe worked hard?

Participants were tested individually and marked "yes" or "no" in a test booklet.

Faux Pas

Mike, a 9-year-old boy, just started at a new school. He was in one of the cubicles in the toilets at school. Joe and Peter, two other boys at school,

came in and were standing at the sinks talking. Joe said, "You know that new guy in the class? His name's Mike. Doesn't he look weird? And he's so short!" Mike came out of the cubicles, and Joe and Peter saw him. Peter said, "Oh, hi, Mike! Are you going out to play football now?"

The subject is then asked the following questions:

Detection of the Faux Pas Question

- Did anyone say anything they shouldn't have said?
- Who said something they shouldn't have said?
- Why shouldn't they have said it?
- Why did they say it?

Control Question

In the story, where was Mike while Joe and Peter were talking?

Received July 14, 2003

Revision received March 8, 2004

Accepted March 18, 2004 ■